

# Thoracic ECMO Guidebook

June 2023

Bianca Bromberger, MD; Meaghan Flatley, MD; Richa Asija DO; Mauer Biscotti, MD; Scott Chicotka, MD;  
Richard Dubois, MD; Joshua Sonett, MD and Philippe Lemaitre, MD, PhD

Philippe Lemaitre, Surgical Director of the ECMO Program



**COLUMBIA UNIVERSITY**  
**IRVING MEDICAL CENTER**

**NOTE:**

This ECMO guidebook is derived from the New York Presbyterian / Columbia thoracic ECMO program.

Based on our experience and local factors, this guidebook reflects our practice and habits regarding devices used, cannulation strategies, interdepartmental organization and patient management.

We advise readers to interpret these in the light of their own environment, device availability and practice.

## Contents

I.	Cannulation and transport supplies checklist	5
II.	ECMO transport run preparation and setup at remote hospital	6 - 7
III.	VV cannulation procedure	8 - 11
IV.	Proned patients	12
V.	Mechanical ventilation on VV ECMO	13
VI.	Repatriation	14
VII.	Peripheral VA cannulation + DPC placement	15
VIII.	Cannula types and selection	16 - 18
IX.	Daily management	19
X.	Decannulation	20 - 22
XI.	Evaluation of bridge to transplant patients	23 - 24
XII.	Tips and tricks	25
XIII.	Cheat sheets	26 – 28

## Abbreviations

ABG	Arterial blood gas
BTT	Bridge to transplant
BTR	Bridge to recovery
CFA	Common femoral artery
CHG	Chlorhexidine gluconate
CO	Cardiac output
CXR	Chest X ray
DPC	Distal perfusion cannula
ETA	Estimated time of arrival
ECPR	ECMO-CPR
IBW	Ideal body weight
LFA / V	Left femoral artery / vein
LIJ	Left internal jugular (vein)
LPM	Liters per minute
LR	Ringer's lactate
MICU	Medical ICU
MP	Multiport
NS	Normal saline
OSH	Outside hospital
OR	Operating room
RFA / V	Right femoral artery / vein
RIJ	Right internal jugular (vein)
RV	Right ventricle
SFA	Superior femoral artery
US	Ultrasound
VA	Veno-arterial
VV	Veno-venous
V-AV	Veno-arteriovenous
VV-V	Veno-veno-venous

**I. Cannulation & transport supplies checklist:**

- 2 x Sterile gowns
- 2 x OR caps
- 2 x OR masks
- sterile OR gloves (fellow, attending, and any assistants)
- 1 x angio drape
- 2 x sterile half sheets (if anticipate needing to set up back-table)
- 2 x packs of blue OR towels
- 2-3 x large CHG prep sticks
- 2-3 x small CHG prep sticks
- 1-2 x sterile lap pads
- 3 x Sterile Kelly clamp (one to dilate the tract at each cannulation site and one to secure the ultrasound probe)
- 1 x Sterile ultrasound probe cover
- 4 x 60cc luer lock syringes OR 2 bulb syringes and a sterile basin
- 2 x 3cc luer lock syringes
- 1 x 18 Ga Needle and 1 x 25 Ga Needle and 3 x 12cc syringes (if awake cannulation)
- 10-12 x 0 or 2-0 Ticron sutures
- 2 chlorhexidine impregnated dressings
- NPH consent form

***Perfusion:***

- Cardiohelp with oxygenator and circuit
- Hand-crank
- Back-up oxygenator and circuit (white container)
- Cannulas and back-up cannulas
- Multiple Estech dilator kits and larger (MC3 or Avalon) dilator kits
- Sterile clamp packs (4 x tubing clamps, shears, needle driver)
- SupraCore progressive wire and Amplatz stiff wire
- 1 x 250cc bag of NS or LR
- EPOC ABG machine

## II. ECMO transport run preparation and setup at remote hospital

### **Initial Consult**

- Transfer center calls with new consult. Intensivist hears consult and may counsel OSH on medical management (i.e. adding iNO, paralytic, vent adjustment etc.).
- If determined to be a good ECMO candidate, intensivist will at this point contact surgical team and discuss case.
- Discuss consult with ECMO transport surgeon on call, including time of availability

### **Upon Acceptance**

- Medical attending will confirm with OSH that they have an US, family for consent (preferably in person), patient will accept blood transfusions (or if refuses that this was known and discussed prior to acceptance), arterial line (if none, preferably request R radial), central line, and position of all central venous access (if possible, request a triple lumen in LIJ if another site is in use. This is preferred but not necessary to save RIJ and RFV for cannulation sites and time at cannulation).
- Confirm patient name and location at OSH (need specific ICU / floor)
- Confirm timing of ambulance pick up. This is handled through the transfer center.
- Call the OSH provider and ask for an ultrasound machine to be in the room, lactated ringers in line, pressors in line, a 5000 unit of heparin IV push (not to be given from the drip), and 1 gram calcium gluconate push – this can take time so communicate this sooner than later
- Have supply bag packed and ready
- Alert perfusion team (they have a 1 hour response time unless someone is in house so factor this into the transport time)
- Discuss with perfusion to ensure they have appropriately sized cannulas packed in the bag (they will need to know the anticipated ECMO configuration and size of patient). Ensure that they have a back-up of each cannula, as well as a 15Fr arterial cannula in case the patient ends up needing VA-ECMO.
- Their transport bag will also contain at least 3 Estech dilator kits, larger (MC3 or Avalon) dilator kits, sterile clamps pack (4 clamps, 1 needle driver, and shears), and an Amplatz wire. They will also bring the Cardiohelp system and a back-up oxygenator and circuit.
- Meet ambulance in front of Milstein with supply bag and perfusionist. Depending on how quickly the team mobilizes, it can be helpful to call the OSH and ask about any changes in the patient's status.

### **En Route**

- Update surgical ECMO attending regarding timing
- EMS paramedics should contact the OSH and asking for duplicates of all drips to speed up the transfer process
- Call OSH provider again and verify that the previously requested medications and ultrasound machine are ready

### **Pre-Procedure**

- Inform surgical ECMO attending of your arrival and let them know the patient's location and room number.
- Find the resident/PA/NP/attending taking care of the patient and go over clinical course to make sure nothing was missed. Ask that they be available to help with medical management peri-cannulation.
- Look at CXR (ensure no mainstem intubation, pneumothorax, etc.)
- Review labs
- Look at bilateral internal jugular and femoral veins with US to assess for size and patency. This allows to calculate ideal cannula size according to patient's full cardiac output and to discuss this with perfusion based on anticipated cannulation strategy – see below.
- Review drips, vitals, and vent settings to make sure all as described and no concerning new developments; there have been times a patient has markedly improved or worsened and ECMO

was no longer appropriate: discuss with medical or surgical ECMO attending any new findings or concerns

- Find patient's family and describe ECMO as machine that does the job of the lungs until the lung problem resolves, but it's not a treatment for the lung problem itself per se. Be up front about the length of hospital stay (i.e. at least a month for most but often longer for COVID ECMO), mortality, and risks (bleeding, risk of injury to nearby vessels, pneumothorax, and hemodynamic instability around the time of cannulation).
  - Consent family for procedure and blood consent
- Ensure that bedside nurse has all drips duplicated for the paramedics. Encourage paramedics to start preparing drips for transfer immediately, as this can take some time
- Ensure bedside nurse has 5,000U IV heparin and 1g calcium gluconate to be given as an IV push available for cannulation. Give the nurse a general overview of how the cannulation will proceed and what their role will be.
- Ensure norepinephrine drip hanging and in line, even if patient hemodynamically stable and not on vasopressors. It is common that patients become hemodynamically unstable post-cannulation or at the time of ECMO initiation.
- Hang LR or NS as volume resuscitation is usually needed in addition to vasopressor requirements upon ECMO initiation
- Have nurse place defibrillator pads on patient. Ensure they are connected to a defibrillator or the connector can easily be accessed when prepped and positioned. Ensure code cart is nearby.
- Most patients will already be on 100% FiO<sub>2</sub> on the vent, the exception being asthma patients with significant oxygenation impairment. For all patients, set FiO<sub>2</sub> to 100% for the cannulation if not on already.
- We advise against major vent, drips or pressors changes until the patient is cannulated on ECMO, as this may prove more detrimental than beneficial at this stage.
  - Exceptions may be for 1) ARDS patients - if the patient is on very high PEEP (>15 cmH<sub>2</sub>O) and is hemodynamically unstable 2) Asthma patients – if there is signs of barotrauma (pneumothorax, pneumomediastinum), high levels of autopeep or hemodynamic instability with concern for dynamic hyperinflation (due to the accumulation of air / gas trapping and decrease in venous return). If this is the case please discuss with the intensivist / medical ECMO attending prior to transfer

### **Setup at remote hospital**

- Set one sterile half sheet over a table and open all sterile contents from your supply bag onto the sheet
- Lay patient flat
- Position vent and tubing in such a way that you have easy access to both groin and neck.
- Tape pannus with Tensoplast to expose the desired groin if needed
- Position the US on the opposite side of the bed to the cannulation sites
- Evaluate the potential depth of insertion of the femoral cannula (either via direct measurement or by recording the patient's height allowing for the use of the rule mentioned below).
- Shave both groins if needed. Prep both groins and upper thigh (because will suture cannula to upper thigh ~ 15cm distal from entry site). Prep neck.
- Gown and glove in sterile fashion
- Place sterile blue towels around b/l groins
- Place angio sheet over patient's lower body
- Drape neck with blue towels then place half sheet. Ensure a wide sterile field around neck (i.e. cover all visible bed and vent tubing), because wire can flop and easily get contaminated
- Have perfusion open up the Estech dilator kits x 2 (and a larger (MC3 or Avalon) dilator kit depending on cannula size) and sterile clamp pack
- Draw up saline or LR into the 60cc syringe or bulb syringe in a sterile fashion (the perfusionist will help you with this).
- Sterilely cover US probe (US should be on opposite side of bed), ensure that there is adequate length to reach neck and groin and use the Kelly clamp to secure probe cover to drapes
- Wait for attending (if not already present)

### III. VV cannulation procedure

#### **Vessel access:**

- Under US guidance, puncture the femoral vein with the 18Ga needle from dilator kit connected to a 3cc syringe. It can sometimes be easier to use the bare needle to gain access, especially in dry patients.
- Because cannulas are much stiffer than central lines, it is critical to puncture the target vein with a shallow angle in order to allow smooth dilation and cannula placement. Also, the general vein axis, the vein puncture site, the tissue tract, and the skin puncture site should all "line up". These principles are particularly relevant for femoral access, especially in obese patients. This requires placement of the skin incision further down the groin as anticipated vein depth increases. In obese patients and depending on anatomy, this critical venous puncture step may require the use of the long 13-cm 16Ga Angiocath to be achieved smoothly.
- Identify the artery (especially SFA) position related to the femoral vein as it can be just superficial to the vein and prevent easy venous puncture. Needless to say that any damage to the artery will be very problematic.
- When the vein is punctured, as evidenced by easy blood suctioning (puncture with syringe) or constant blood backflow (bare needle technique), insert the wire to an appropriate depth (or until you see ectopy on monitor). The wire should go in without ANY resistance. Can also look at the right internal jugular vein on ultrasound to confirm the wire in the femoral vein. If using the EOPA cannula, can consider using the shorter wire that comes with the cannula
- Remove needle.
- While keeping the wire in place, re-sheath the wire in the plastic ring to prevent contamination.
- Gain access to the second vessel in the same manner and again re-sheath the wire.

*Sometimes, using a pre-placed central line access (usually in the jugular vein) may be tempting to "speed up" the cannulation process. This should be avoided as sterile manipulation of old lines is always dubious. Also, because these lines were placed either for other purposes or by ECMO-naïve practitioners, the puncture principles developed above are usually not respected. In our experience, a fresh puncture made in the purpose of cannulation usually proves more efficient and is safer. Exception to this rule should be limited to patients who present very challenging vascular accesses (short neck, morbidly obese, limited access points), and in whom the balance between the risks and benefits favors attempting at reusing a previously-placed access. In these cases, central lines may not accommodate a .035 wire and an additional step using a smaller (.025 or .018) wire will be needed, with exchange for a .035 once the first dilator is in place. Be careful that the inner channel of the dilator is too large for a <.035 wire which leaves a step at the tip of the dilator. Dilator must be smoothly pushed over such small wire to avoid vessel tearing.*

#### **Dilating the vessel:**

- When ready to dilate, make first the skin incision around the wire, up to the anticipated cannula size. Gently dilate skin and underlying tissue with a mosquito or Kelly clamp.
- Slide the dilator on the wire and use opposite hand to give counter tension on skin while advancing dilator through tissues into the vein. Pause after each advancement of ~1-2cm and use opposite hand to gently slide the wire in and out of dilator to ensure no kinking. Insert the dilator up to the desired depth to dilate the vein. Again, the stepwise dilation process should occur smoothly. Dilation can be challenging in very obese patients with the risk of wire kinking.

*Once kinked, the wire can no longer be safely used and must be discarded. First, because a kinked wire does not allow smooth wire gliding, and second because a kinked wire will result in breaking/tearing of the dilator tip, which can further result in vascular wall injury. To exchange the wire, do not use the same dilator which caused the wire to kink. Instead, reinsert the previous, smaller dilator and then exchange for a new wire. Be mindful of the friction generated by a kinked wire to avoid pulling both wire and dilator at the same time as this would result in losing the vessel access.*



*Exchanging for SupraCore progressive wire or Amplatz superstiff wire can be helpful. The Amplatz is not initially designed to cannulate veins and these must therefore be manipulated cautiously. Gentle force must be used when introducing the wire in the venous system.*

- To remove the dilator, have an assistant stabilize the wire, then pull the dilator. Pinch the skin insertion site or hold gentle pressure over the site, taking care not to kink the wire
- Once the dilator is out of the skin and you are holding pressure over the site while pinching the wire, slide the dilator back along the wire to a place that your assistant can easily reach, let go the dilator, hold the wire and say "I have wire". Indeed, wires tend to get backed out with each dilation and dilator removal.
  - This is especially important while dilating the jugular veins as there is often much less wire length inside the vein. Push the wire back a few centimeters into the patient after each dilation in order to ensure adequate position.
- Leave the last dilator in place over the wire and re-sheath the wire in the plastic ring before dilating the second vessel.
- After dilating the second vessel, again leave the last dilator in place and re-sheath the wire.
- Once both vessels have been dilated to the appropriate size, ask the nurse to give 5000U of Heparin IV. Allow at least 3 minutes of circulation while you prepare the cannulas and tubing. Lower amounts (2000U-3000U) or even no heparin at all can be used in either very small patients or coagulopathic patients, respectively.
- In instances when ECMO initiation is planned with no or limited heparin, the cannulas can be initially flushed with saline to avoid stasis of blood in the cannula before ECMO initiation.

#### **Preparing the tubing and cannulas**

- Take tubing from perfusion; clamp using sterile blue clamps at the tape marks with scissors icon, disconnect at the white plastic connectors.
- Estimate length of tubing needed for reinfusion (red markings) and drainage (blue markings), clamp and cut approximately 5cm distal from the clamp.
- Have perfusion hand over the cannulas in a sterile fashion. You will have to assemble the cannulas: attach colored cap (red or blue) to the end of the cannula that will eventually attach to tubing. Then insert the white inner obturator into the cannula. Keep the supplies (smaller wires, scalpel, additional dilators) that come in the cannula packaging in case they are needed later in the procedure. If using an arterial reinfusion cannula that has a side luer-lock, check the cap is well secured, or connect a three-way connector if using a distal perfusion cannula).

#### **Insertion of the cannulas and connection of the ECMO tubing to cannulas**

- After 3 minutes of heparin circulation, remove the dilator at your planned groin drainage site (while holding pressure).
- When inserting and advancing the cannula over the wire, your assistant must:
  - Pay attention to sterility of the floppy wire and cannula as lengths manipulated will be greater at this specific moment.
  - Keep the inner obturator well inserted in the outer cannula, by keeping the distal ends in contact. Indeed, inner and outer components must be inserted in a joined fashion to avoid creating a step between the inner and the outer parts. This can occur if the actual cannula disjoins from the inner obturator when pushed "alone" and can result in cannulation issues and vessel tearing. The modern long venous cannulas come with an extended obturator that must be pulled when the tip gets closer to the heart. Therefore, when 30cm of cannula have been inserted, the obturator must be pulled back 5cm (there are markings), to minimize the risk of cardiac injury.

- Advance the drainage cannula over the wire to the appropriate depth. The ideal position of the tip of the drainage cannula is at the IVC-RA junction.
  - *Right* femoral drainage
    - 70in person ~ 50cm depth
    - 66-70in person ~ 45cm depth
    - 60-66in person ~ 40-42cm depth
  - For *left* femoral drainage, advance about 3-5cm further than listed above. This accommodates for the slightly longer distance from left femoral vein to the IVC-RA junction.
  - In patients who are obese or have significant edema, the drainage cannula will need to be inserted further than expected based on height alone, as distance from skin is longer
- Advance the cannula deep at the start. It can always be pulled back, but cannot be advanced once the sterile field is broken.
- Remove and re-sheath wire, then remove obturator slowly while allowing blood to backfill the cannula. Applying pressure on the liver at the moment of back bleeding the cannula can help the filling in very dry patients.
- When about to overflow, clamp the cannula using a clamp at approximately 3-5cm from end. Ensure there is no air trapped in proximal part of the cannula. Unclamp and back bleed again if need be.
- Remove the colored cap.
- In instances when ECMO initiation is planned with no or limited heparin, flush the cannula with saline.
- After cross-checking that the *venous* line will be connected to the *drainage* cannula, bring the venous line end in the vicinity of the cannula end and drip NS or LR from the 60cc syringe into both clamped ends. Achieve connection “under water” to avoid any air bubble in the system.
- Ensure no air in tubing/cannula before and after removing the clamps
- Repeat the same procedure for reinfusion cannula
  - RIJ: advance to the double blue line on the EOPA (~20cm)
  - LIJ: advance to double blue line or slightly deeper
  - Fem-fem VV: The reinfusion cannula should be approximately 3-5cm deeper than the drainage cannula. The simplest way to do this is to plan to use the RFV as reinfusion (R = reinfusion = right) and the LFV as drainage. Insert the drainage cannula into the LFV at the length listed above and then insert the reinfusion cannula to the same length (the discrepancy in the longer distance traveled from the left compared to right femoral veins should put the tips at the appropriate relative distance). For example, for a 67in person, the drainage cannula would be first inserted in the LFV to a depth of 48-50cm. The reinfusion cannula would then be inserted in the RFV to the same distance (48-50cm).

*Do not take your hand off of the jugular reinfusion cannula until it is secured. This cannula does not have a lot of purchase and has positive pressure, so it can come out very easily*

#### **Initiation of ECMO:**

- Have the nurse give the entire 1g bolus of Calcium gluconate as cardiac stabilizer
- Remove clamps on the reinfusion side and begin ECMO flow
- ECMO flow is started at 1 LPM and sweep matched 1:1 at the start. Increase flow by 1LPM every 30 seconds to a minute until you reach the desired flow. Target flow depends on patient size and oxygenation needs: VV ECMO flow must be >60% of the patient’s actual cardiac output to achieve oxygen saturation >90%. Large patients and septic may need >6L ECMO flow to be well oxygenated, hence the need to place the largest possible cannulas. Dry patients will need their intravascular compartment filled to flow adequately, up to a few liters may have to be infused over the first post-cannulation hours.
- In severely hypercapnic patients (typically status asthmaticus), do not titrate sweep to more than 2LPM without checking ABG. It is important to not rapidly or overcorrect CO<sub>2</sub> in these patients as it places them at risk for cerebral vasospasm / hemorrhage. (As an example, in a patient with status

asthmaticus with a pre-ECMO pH of 7.0-7.1, an appropriate ABG 5-10 min post-cannulation may have a pH no more than 7.2-7.25). Correction of hypercapnea and normalization of pH can occur over the first several hours on ECMO.

- Watch patient's hemodynamics during titration of ECMO flow.
  - Norepinephrine is usually at least transiently needed
  - Volume resuscitation may be needed to achieve stable ECMO flow due to the increased volume of distribution and vasodilation following ECMO initiation, particularly if the patient is intravascularly depleted prior to ECMO.
  - Myocardial function recovery following gases stabilization may allow downtitration of norepinephrine down after some time
  - Evaluate for other potential causes according to cannulation process: bleeding (rough femoral cannulation?), pneumothorax (dubious neck puncture?), decreased venous return (from extremely high PEEP or gas trapping / dynamic hyperinflation).
- Any dubious step during cannulation or upon ECMO initiation should prompt process review and, if needed, urgent CXR or abdominal XR as initial assessment tools.

### **Securing the cannulas:**

- Secure the neck cannula first. This should be done while monitoring patient vitals and titrating the ECMO flow and sweep.
- Place a 0 or 2-0 Ticron purse-string around the insertion site and attach to the cannula
- Place 0 or 2-0 Ticron stitches at the skin just distal to the insertion site (similar to chest tube stitch), then place a second on the opposite side. Then place additional stitches distally in the same manner (usually place about 5 stitches per cannula). *Do not place any of the Ticron sutures at sites where the cannula is tapered (the suture will become loose).*
- Clean insertion site with chloraprep, allow time to dry and cover the site with CHG dressing
- Turn attention to the drainage cannula and ensure that there is minimal recirculation (drainage blood should be much darker than reinfusion, pre-oxygenator saturation should be in the 70s to low 80s, no bright red flashes in drainage cannula). If still unsure about re-circulation, can ask perfusion to obtain and pre-oxygenation ABG and look at the SvO<sub>2</sub>.
- If there is significant recirculation, slowly retract the drainage cannula at 1cm intervals while monitoring for improvement.
- Don't secure the drainage cannula or breakdown the sterile field until you've achieved adequate flow, recirculation is minimized, and the patient's saturation has improved appropriately.
- Once cannula is in the appropriate position, place another Ticron purse-string and four Ticrons around the groin cannula in the same manner as above.
- Clean insertion site with Chloraprep and again place a chlorhexidine impregnated dressing around the insertion site.
- The neck cannula will need one or two additional stitches to maintain a straight alignment, ideally coursing behind the patient's ear. You should do these stitches after the CHG dressings are in place to maintain sterility. Often you have to free up the ETT strap (after stitches are placed be sure to re-secure with the cannula underneath) and aren't able to prep the area adequately prior to starting the cannulation, so easier to leave these sutures until the end. A total of 5 stitches should be placed in the neck and 5 – 7 in the groin.

#### IV. Proned Patients

Patients with ARDS who have failed proning can be among the sickest patients needing ECMO and require some extra planning to ensure a quick but safe cannulation. Sometimes (though not always) when they are turned supine, they can rapidly desaturate and become hemodynamically unstable.

- Keep patient in prone position until you are done with the evaluation and family discussion and are ready to cannulate.
  - Sometimes the OSH, with the intent of preparing for ECMO team arrival and cannulation, will say they can unprone the patient prior to your arrival; do not let them do this for the above reasons.
- Discuss with bedside nurse and OSH MD the plan for cannulation:
  1. The OSH ICU MD must be present during the cannulation to focus on managing hemodynamic instability, desaturation, etc. while you focus on cannulating. In the event of profound desaturation despite aggressive mechanical ventilation, the patient may require manual bagging during the procedure (RT or MD).
  2. At least 3-4 other people are needed to
    - Turn the patient quickly
    - Unpad patients. Indeed, these patients are often proned in specific beds (RotoProne) which have lots of padding around body and head that needs to be removed when supine. Have multiple people removing it at the same time. Patients can be cannulated when supine on the RotoProne bed, no need to move to a regular bed.
- Before unproning:
  1. Place defibrillator pads on patient.
  2. Position vent, US machine, etc.
  3. Prepare the sterile back table or two on which you open all your supplies, clamp pack, dilator kits, cannulas, and prepare filled syringes
  4. Be gowned and ready to prep as soon as the patient is adequately exposed
  5. Morbidly obese patients will need pannus taped to gain adequate exposure before prepping

#### **Strategy:**

Fem-fem VV is quicker, easier and therefore safer in these patients, but all sites must be prepped and draped to prepare for all possibilities. Examining all sites with US might not be possible prior to cannulating an unstable patient.

If, once supine, patient is not markedly desaturating or otherwise unstable, the procedure can be slowed down a bit and VV cannulation can be carried out in a standard femoro-jugular fashion.

## V. Mechanical ventilation in patients initiated on VV ECMO

The overall goal is to minimize injurious levels of mechanical ventilation in ECMO-supported patients. This includes minimization of end-expiratory plateau pressures (that place the patient at risk for ventilator-induced lung injury and pneumothorax) and dangerous levels of extrinsic and intrinsic PEEP (i.e. auto-peep) that place the patient at risk for hemodynamic compromise. However, it is important to note that significant changes to the ventilator should occur over hours, primarily to be done by the accepting ICU team following cannulation and ECMO transport.

- *Ventilator adjustments:*
  1. Ventilation: as ECMO sweep is extremely effective at CO<sub>2</sub> removal, changes to tidal volumes and ventilation rate can be set to more stable levels for transport.
    - There is no exact science for how much to reduce the minute ventilation per liter of sweep. Each patient's needs are different, so make small changes (1 LPM of sweep at a time) and check gases 5-10min after each change on the ventilator and ECMO settings.
    - For patients with exceptionally high CO<sub>2</sub> and respiratory acidosis, sweep up-titration must be slow, as dramatic swings in CO<sub>2</sub> carry a risk of cerebral vasospasm, seizure, hemorrhage and stroke. It is better to undershoot than overshoot sweep gas titration. This correction must occur over few hours to be safe.
    - Decrease the tidal volumes at 6 cc/kg IBW so that peak airway pressures are no more than 40 cm H<sub>2</sub>O for transport, if possible.
    - Reduce respiratory rate to a moderate level (typically 20-24 breaths per minute. For asthma, reduce respiratory rate until there is minimal or no auto-PEEP (measured with an end expiratory pause maneuver), particularly if a patient is hemodynamically unstable.
  2. Oxygenation: Don't make too many changes and keep oxygenation optimized for transport, as it's possible patients may derecruit during transport:
    - DO NOT adjust PEEP for transport to avoid derecruitment, unless excessively high (> 15 cm H<sub>2</sub>O or higher) or if there is significant hemodynamic compromise that may be improved with reduction in PEEP and resultant increase in preload.
    - You can keep patient on 100% FiO<sub>2</sub> or can start to wean. For asthma patients who have little to no oxygenation impairment, FIO<sub>2</sub> can be titrated down.
- Obtain ABG 5-10 minutes after every ventilator change and adjust ECMO blood flow and sweep accordingly. Vent and ECMO settings can be changed at the same time without checking a gas in between, but a final ABG on the vent and ECMO settings intended for transport must be controlled. Transport vent settings must be transmitted and confirmed with paramedics. Of note, volume control ventilation may be preferred to pressure controlled ventilation, as patients may otherwise hypoventilate during a bumpy ambulance ride (due to pressure limits being reached). If there are any questions about ventilator settings prior to ECMO transport, contact the ECMO attending on call.

## VI. Repatriation

### ***Preparing the patient for transport:***

- Remove all sharps and break down the sterile field.
- If easy to obtain, a CXR could be done, but this step is not mandatory. If cannulation and ECMO initiation were smooth, this should not delay patient repatriation
- Record initial cannula depths by measuring the distance from skin incision to the end of the wired portion of the cannula.
- The paramedics will begin their process of transferring drips over to EMS pumps (if not already done pre-cannulation) and preparing the patient transfer to the stretcher.
- After the patient has been on ECMO for 5-10 minutes at a flow rate that has appropriately improved their saturation and a sweep between 2-3L/m, check a patient ABG before adjusting the ventilator (see ventilation strategy).
- Ensure that perfusion zip ties the cannula and tubing connections
- Talk with the family and let them know how the procedure went
- Help paramedics move the patient to the stretcher while keeping the cannulation sites exposed to ensure the tubing doesn't get caught or cannulas don't get pulled
- Ensure that you and perfusionist are comfortable with how CardioHelp is secured to the transport tray (i.e. straps are tight, not compressing any latches that cause oxygenator to detach from pump head, etc.)
- Make sure OSH nurse calls ICU to give report.

### ***En route back***

- Let the ICU team know that you are en route and how the procedure went
- Position yourself in the ambulance so that you can see the VS and can titrate drips etc.

### ***In repatriation ICU***

- Discuss cannulation with accepting provider
- Check that cannula depths of insertion haven't changed during transport.
- Let the NP know of anything that was missing from the initial consult or any additional data
- Ensure CXR and ABG are done stat
  - Check correlation between cannula depths and position of cannulas on Xray
  - Check CXR if concerns for recirculation or PTX
- Leave Procedure Note and let attending surgeon know patient is safely in the ICU

## **VII. Peripheral VA cannulation and DPC placement**

### ***Venous drainage***

- Guidelines for venous drainage cannula placement are identical to the VV drainage cannula described above. The cannula tip should sit in the same location (IVC-RA junction) for VA cannulation or even a little higher as there is no risk for recirculation.

### ***Arterial cannulation***

- With US, identify the bifurcation of the femoral artery into profunda and SFA, then go proximally to identify CFA.
- Access CFA, place the .035 wire, and proceed with cannulation as described above, except that cannula will be a reinfusion 13, 15 or maximum 17Fr arterial cannula.
- Hand secure the arterial cannula at all times until sutured. Again, this one is short, under positive pressure and can get dislodged easily.

### ***Assessment of distal perfusion catheter (DPC) requirement***

- In hemodynamically unstable patients, proceed with VA cannulation first and determine need for DPC once on ECMO. In these unstable patients, keep the vasopressor levels during cannulation, even if these seemingly overcorrect systemic blood pressure.
- If the patient is relatively stable and you are doing percutaneous cannulation, place a micropuncture wire distally in the SFA for a DPC prior to cannulating the CFA. It is much more difficult to access the SFA once the arterial cannula is already placed.
  - Alternatively, you can measure the CFA and SFA to determine the likelihood of needing a DPC and use those measurements to decide whether or not to place a wire in the SFA.
- Distal perfusion is needed in the face of:
  - small femoral vessels
  - marked leg saturation discrepancy or leg saturation <60%
  - clinical signs of distal hypoperfusion
- If the patient's vessels were relatively large and no signs of impaired perfusion once on ECMO, either remove the wire or leave in for a short period of time. In this case, the wire must be secured because dislodging could result in distal wire embolization.

### ***Percutaneous DPC cannulation technique***

- Requires the Micropuncture Introducer Set, 8Fr Pediatric aortic cannula, Pediatric insertion kit (for 0.025 wire), and DPC tubing
- Under US visualization, access the SFA using the green 21Ga needle from the micropuncture kit. Puncture should be just distal to SFA origin in trying to avoid an area of stasis between the arterial cannula and the DPC, but also to avoid accidental cannulation of the profunda. Arterial back-bleeding confirms adequate localization but can be difficult to confirm
- Insert the wire from the micropuncture kit into the SFA and remove the needle.
- Insert the 4Fr sheath over the wire, then remove the wire.
- Then insert the 0.025 wire from the pediatric insertion kit (the Estech dilator is 0.035in and too large for the pediatric aortic cannula)
- Dilate to 8Fr, insert the DPC (8Fr Pediatric aortic cannula), remove the obturator, back-bleed (may be slow), and clamp the cannula.
- Connect the DPC tubing to the end of the cannula, and back bleed through the tubing (or fill with saline – just ensure no air in the DPC tubing or cannula), then reclamp at tubing end.
- Will then need to come off ECMO – clamp arterial line on either side of the DPC connection site.
- Unscrew white cap, and attach DPC tubing to the arterial cannula connection point, ensuring no air is introduced into the system.
- Unclamp all lines and go back on ECMO.

## VIII. Cannula Types & Selection

### **Cannula types:**

- *Venous Cannulas for drainage:*
  - Biomedicus Multiport (Multi-Stage Venous Cannula® - 19Fr, 21Fr, 25Fr, 29Fr): Drainage holes evenly spaced along the distal 25cm of the cannula. Designed to sit with distal end in SVC to drain SVC, atrium and IVC, but can also be positioned similar to the end-hole cannulas)
  - Maquet Multiport 25 and 29Fr: similar design to the Biomedicus but shorter in length. Should be inserted “all the way”.
  - End-hole (comes in 19Fr, 21Fr, 23Fr, 25Fr, 27Fr, 29Fr): Drainage holes only at the distal 3cm of the cannula. Note: the 25Fr Biomedicus End-hole connects to ½” tubing rather than ⅜” and so requires an extra piece of ½” tubing and the ½” to ⅜” connector.
  - BiCaval (Next-Gen ®): Drainage holes at the very tip of the cannula and then about 15-20cm proximally, designed for bypass cases to drain the SVC, no drainage in the atrium, and then again drain the IVC.
- *VV Reinfusion:*
  - IJ reinfusion: EOPA “Elongated One-Piece Arterial” (18Fr, 20Fr, 22 Fr, 24Fr).
  - Fem-fem VV: the same end-hole drainage cannulas as above are used as reinfusion cannula
  -
- *VA reinfusion:*
  - Biomedicus Femoral Arterial Cannula (15Fr, 17Fr, 19Fr)  
The reinfusion holes are just located at the cannula end. It also has a side port with a luer lock cap to attach DPC.
  - EOPA (same as above): used for aortic cannulation in central ECMO
- *Dual-Lumen for VV (Avalon® / Crescent®):*

Dual lumen single site cannulas are designed to be inserted in RIJ with drainage ports in SVC and IVC and reinfusion jet directed into RA, across the tricuspid valve. These must be placed in the OR under fluoro +/- TEE to ensure proper positioning and reinfusion jet appropriately aimed.

On rare occasions, such as large intracardiac defects (ASD / PFO >2cm, PDA) with right-to-left shunting, such cannula can provide a modicum of arterial support, as directing the reinfusion port across the defect oxygenates the right-to-left shunt. Of note however, this will not be of any help in the face of right heart decompensation, and these hemodynamically failing patients need VA ECMO. The dual-lumen cannulas are not versatile which limits their use to specific cases.

These cannulas are dual-lumen, providing both drainage and reinfusion and benefit those patients that will be extubated and working with PT (e.g., BTT patients).  
Range in size from 24-32Fr.

Drainage holes exist at the distal end (intended to reside within the intrahepatic IVC when placed appropriately) and the mid-portion (intended to reside within the SVC when placed appropriately).

The reinfusion pore is between the two sets of drainage holes and, when appropriately positioned, resides within the RA directed towards to tricuspid valve.
- Candidate selection:





- Ideal candidates for this cannula are those patients that you predict will not need high flow rates given that these cannulas tend to max out around 4.5 to 5LPM (under ideal conditions).
- Patients with predominantly hypercarbic respiratory failure (e.g., CF patients) can usually be easily supported with this cannula model given that they do not typically require higher flow rates. However use of a dual lumen (or smaller cannula in general) must take into account hypoxemia that while not present at cannulation, may develop during the ECMO run. For example, CF patients can have significant mucous plugging / secretion impaction and become hypoxemic over time, even if their primary indication for ECMO was hypercapnea.
- Pitfalls:
  - Patients with long-standing RIJ access or long-standing central access in general may have some component of central venous stenosis and, thus, can be less than ideal candidates
    - These cannulas can be placed from the LIJ but this is suboptimal and technically more challenging
  - The orientation of the reinfusion pore towards the tricuspid valve is important and changes in this orientation can result in more recirculation, thus making it crucial to orient and secure the cannula well.
  - Placement:
    - Placement of these cannulas is ideally done in the operating room with fluoroscopy and TEE capabilities.
    - Patient should be on fluoro-compatible bed with arms tucked
      - Shoulder roll perpendicular to spine, under the scapula can help with RIJ exposure
    - Patient will require GA for TEE
    - Prep the RIJ wide

**Cannula selection:**

- *Venovenous drainage:*
  - The limiting cannula for blood flow is almost always the drainage cannula. Cannulas have associated flow charts that estimate what flow can be achieved at different negative pressures, but these flow rates are calculated using water (much less viscous than blood) and assume perfect positioning. The rule is always to overestimate target flow.
  - The patients' estimated cardiac output (BSA X 2.4) is used to calculate the predicted pump flow needed ("target flow"), providing a VV ECMO flow >60% of the actual CO has been shown to achieve a saturation of >90%. However, this represents physiologic CO baseline. Critically ill patients, particularly those with ARDS who are septic / hyperdynamic, will have an actual CO much higher than predicted CO, thus have flow requirements higher than predicted CO to meet physiologic demand.
  - ARDS patients: choose the largest cannulas that can safely fit in the patient's vessels without compromising distal flow in order to allow the greatest ECMO flow. Except for very small patients, most patients can accommodate a 29Fr Multiport drainage. This cannula can be used for drainage in both in fem-fem and fem-IJ configuration.
  - Asthma patients showing no oxygenation impairment are the exception to selecting large cannulas. In these patients, no more than 2-3L/m blood flow is needed for decarboxylation, which can usually be achieved with a 21Fr Biomedicus drainage and an 18Fr EOPA (fem-IJ) or 19Fr Biomedicus reinfusion (fem-fem).
  - Asthma patients presenting ANY concern for impaired oxygenation (infiltrates on CXR, increasing FiO<sub>2</sub> requirements, etc.) need larger cannulas. Flow overestimation is again the golden rule.

- BTT patients: while VV ECMO is typically adequate for patients with CF awaiting lung transplantation, patients with ILD generally require VAV ECMO in the context of associated pulmonary hypertension. However, VV bridged patients should receive a large drainage cannula because even initially hypercarbic patients can become hypoxemic over time.
- *VV reinfusion cannula*
  - For fem-fem, choose a slightly smaller cannula for reinfusion (i.e. 29 or 25Fr Multiport drainage & 21Fr or 19Fr Biomedicus end-hole reinfusion, 23Fr Biomedicus end-hole drainage with 21Fr or 19Fr Biomedicus end-hole reinfusion.)
  - For fem-IJ, the EOPA reinfusion almost never is the limiting factor for flow as it is short and relatively wide. If any difficulty dilating the neck, the 18 or 20Fr EOPA is usually sufficient if you cannot fit a 22Fr easily. If planning to use a large drainage cannula (e.g., 29Fr multiport try to place 22Fr EOPA in IJ if vessel diameter permits).
- *Venoarterial*
  - The standard cannulas sizes are 15Fr arterial Biomedicus for reinfusion and 25Fr Biomedicus End-Hole for venous drainage (small patients may be OK with 23Fr cannula, while larger may require larger ones, the goal being always to place the largest drainage cannula possible).
  - In patients with small femoral vessels (<7mm), the 15Fr arterial cannula has a high chance of impairing distal perfusion. If not emergent, obtain a smaller cannula (14Fr), but these small cannulas can require extra supplies:
    - A Pediatric Insertion Kit with a .025 wire as the 14Fr cannula doesn't accommodate the 035 wire that comes in the Estech kit.
    - The 14Fr cannula ends on a 1/4" connector and therefore requires a smaller tubing portion plugged into a 1/4"-3/8" connector before being attached to the standard 3/8" ECMO tubing line.
- *Differential Hypoxemia and the need for VAV ECMO*

Any patient bridged with peripheral VA for hemodynamic support with impaired oxygenation and an ejecting heart is at risk of developing differential hypoxemia (dual circulation). In this situation, the upper body and brain receive poorly oxygenated blood from native LV ejection, as opposed to more distal well oxygenated perfusion that comes retrograde from the femoral arterial reinfusion cannula. The mixing point between these two opposing flows depends on the balance between the native cardiac output and the ECMO blood flow and may mean that while the lower body (or possibly lower and left side of body) receive well-oxygenated blood from the ECMO circuit, the upper body (or right side of upper body) may receive poorly oxygenated blood from the native cardiopulmonary circulation. As the innominate artery and right radial artery being closest from the aortic valve, the best assessment of such phenomenon is obtained with a right radial ABG. In the advent this confirms presence of dual circulation with low PaO<sub>2</sub> and saturation, the patient needs to receive an extra reinfusion limb via a jugular vein to convert from VA to VAV ECMO. In this setting, the blood flowing through lungs is already well-oxygenated as in a VV system (which controls the watershed phenomenon) and the patient continues to receive hemodynamic support from the arterial femoral limb.

Because it splits reinfusion in two (via a Y 3/8"-3/8"x2 connector), such VAV mounting requires higher drainage flow and may need anticipated placement of a 25Fr or larger drainage cannula. Although oversized when used with a single 15Fr reinfusion arterial cannula, the 25Fr drains up to 5L/min which can be comfortably split with the appropriate Hoffman clamp into 3L towards the A limb and 2L towards the V limb in the VAV mounting and subsequently adjusted based on physiologic needs.

## **IX. Daily management**

### ***Rounding / clinical work:***

- Examine patients, labs, CXRs, chest tube(s) output(s) and other relevant imaging / testing
- Check ECMO
  1. Circuit: gas exchange, pressures, ML delta pressure
  2. Cannulas securement (static assessment: visual at skin, depth on CXR) and tease cannulas (dynamic assessment): this is especially important for awake and ambulatory ECMO patients. PT will ask you to review and confirm appropriate cannula securement prior to mobilizing the patient. It is equally important to review in other patients as they may have to be mobilized at any moment, e.g. to go to CT scan in the middle of the night in the face of suspicious neuro finding.
    - It is important to remember that sutures can break to the skin yet still be present on the cannula itself, so that on a quick glance it looks like sutures are intact but really, they are no longer secured to skin and just intact to the cannula itself.
- Evaluate each patient's clinical course and question:
  1. Support requirement with the goal of discontinuation of ECMO as soon as possible (except for BTTs)
  2. Support adequacy, ways to improve if needed (volume status, drainage cannula position) and potential need for reconfiguration (VV VAV? Central?)
  3. Ventilatory rest strategy (remember the best vent rest maybe no vent: question extubation)
  4. Adequacy of anticoagulation strategy
- When appropriate, question timing for tracheostomy

## **X. Decannulation**

### ***Preparation***

1. Have ICU stop heparin 2 hours prior to any decannulation
2. Call perfusion and let them know timing.
3. Consent family (or patient if awake and consentable)

### ***Decannulation from VV ECMO:***

#### *Supplies:*

- 2 gowns/gloves/hat/mask
- 2-3 packs of blue towels
- Large Chlorhexidine prepsticks
- Gauze or 1 pack lap pads
- 4 x 0 or 2-0 Prolene
- 25Ga & 18Ga needle
- 12cc syringe
- Basic suture tray or 4 kelly clamps and scalpel
- 20cc lidocaine
- CHG dressing x 2
- Sterile clamp pack from perfusion (tubing clamp x 4, shears, needle driver)
- If able to acquire, could open 1 pack of small clips and 1 pack of medium clips
- Vessel loops

#### *Procedure*

- Ensure adequate sedation/analgesia
- Position bed flat, head slightly up
- Expose cannula sites, remove CHG dressings and prep around cannulas
- On the femoral drainage line, have someone hold up the tubing so it is not touching patient and prep line all the way down so that 10-15cm of tubing (not cannula) are prepped in (the tubing is what connects to the re-infuser, not the cannula). Place a blue towel underneath and rest prepped tubing on towel.
- Place additional blue towels around the groin cannula site and similarly prep the IJ reinfusion (or contralateral groin).
- Gown and glove, get sterile clamp pack from perfusion and draw up lidocaine.
- Inject 5-10cc 1-2% lidocaine around each cannula insertion site.
- Cut and remove sutures around groin drainage cannula insertion site.
- Starting with the drainage cannula site, place two hemostatic purse string stitches with 0 or 2-0 Prolene around groin cannula. Cut needles off and clamp sutures to the side.
- When perfusion ready and attending present, double clamp venous drainage tubing about 6cm apart and cut in between clamps
- Hand off end going to pump to perfusion -- they will then connect to reservoir
- Tell perfusion to give back circuit volume 100cc at a time, while monitoring BP or PAPs (if Swan). There is about 400-500cc in circuit.
- While perfusion is giving back volume, have assistant hold pressure on either side of the drainage cannula insertion site while you prepare to tie down suture. Have assistant pull cannula back and clamp cannula with tubing clamp to prevent blood spilling out of cannula (at 15cm for end-hole or 35cm for Multiport). Once cannula clamped, assistant removes cannula and holds pressure with the other hand, Tie suture down once cannula is out. There will be a fair amount of blood spillage especially out of the Multiport cannulas. The assistant has to pull cannula quickly to minimize period when cannula tip is still in the vein while holes start coming out at the skin.
- Once all blood is returned, have assistant continue holding pressure on the groin and turn attention to neck cannula (or other groin cannula). Remove sutures and place sutures

around cannula similarly to described above (or you can do this prior to pulling the drainage cannula but leave one stitch in to prevent the cannula from becoming dislodged).

- While assistant is still holding pressure on groin with one hand, have them hold pressure on either side of reinfusion cannula insertion site. Clamp cannula to prevent blood spilling from cannula. You then pull out cannula while assistant is holding pressure and tie down.
- Hold pressure for 5-10 minutes depending on coagulopathy. Clean sites and apply CHG sterile dressings. Patient should lay flat for at least 2 hours.
- Sutures can be removed in 7 days or longer depending on the patient.
- Obtain surveillance venous US of sites to check for DVTs.

### ***Decannulation from VA ECMO:***

Can be done in the OR or bedside in ICU

If bedside, supplies are:

- Minor vascular tray from OR
- Cautery
- Free wall suction canister & tubing
- Light source and head-lamp x2
- Gowns, hats, gloves, masks x 3
- Large CHG prep sticks
- 2 x sterile blue towel pack
- 2x split drapes
- 1 x Lap pads
- 2 x Sterile gauze pack
- 1 x Yankauer suction
- Sterile suction tubing
- 60cc syringe with injectable saline for irrigation
- Multiple 6-0 and 5-0 Prolene for arterial cannula
- 2 x 0 or 2-0 Prolenes for venous cannula
- 0 vicryl, 2-0 vicryl, 3-0 vicryl
- 0 and 3-0 silk ties for ligating superficial vessels
- Skin stapler
- Gauze and Tegaderm for dressing
- Also good idea to have 4Fr and 5Fr Fogarty balloons with appropriate syringes
- 

#### ***1. Decannulation of the arterial limb and arterial repair / closure***

- Prep in both groins, cannulas, and venous tubing as above. Discuss with surgical and anesthesia attendings prior to case about utility of intra-op TEE. Usually it is customary to have either swan or TEE when coming off VA ECMO. It is easier to get when the procedure is carried out in the OR but TEE should be available in ICU as well.
- To be safe, it is often a good idea to have iNO readily available (i.e., in the room) in the event PAP rise after coming off.
- Take note of starting leg sats
- Make incision superiorly over the arterial cannula and dissect down to artery.
- Techniques vary at this point. The **gold standard** should be to isolate the CFA and its divisions above and below the cannulation site with vessel loops (around the proximal CFA, profunda, and SFA). Then place a Satinski clamp around the proximal CFA and bulldogs or other vascular clamps around the SFA and profunda. Clamp off distally first, then pull cannula out and clamp the CFA. Backbleed profunda, SFA, and then CFA once clamped. Debride the arteriotomy edges of any loose adventitia. Close the arteriotomy with 3-5 interrupted 5-0 or 6-0 prolene ensuring to take each bite inside-to-out. Tie down sutures from outside-in. Back bleed SFA a bit first then reclamp and come off CFA clamp slightly de-airing into profunda. Tie down remaining sutures, remove all clamps, and palpate distally.

- Some attendings prefer just getting the artery exposed on the anterior surface and placing 1 to 2 purse string sutures around the arteriotomy with 5-0 or 6-0 prolene and then pulling the cannula and snaring down the sutures. This method is faster, however has a higher rate of vessel stenosis. It is therefore preferable to use only in large CFAs (8mm and above for a 15Fr cannula). Furthermore, if the purse strings don't control the arteriotomy, you will then have insufficient proximal and distal exposure to control it adequately for repair.
  - Prior to coming off, circuit should be reduced to 1LPM of flow with monitoring of hemodynamics (and TEE if present). This can require HD management with vasopressors or some Dobutamine by ICU team.
  - Test clamp circuit to ensure patient tolerates coming off VA support prior to cutting lines.
  - Clamp and divide venous tubing, pass off to perfusionist for auto-transfusion, return circuit volume if hemodynamics allow and depending on RV look on TEE
  - Remove venous cannula and hold pressure as above.
  - Remove arterial cannula. If patient has a DPC, this can be clamped off while removing retrograde arterial cannula and repairing primary arteriotomy. If DPC puncture site is in the field, the DPC can be pulled and the site snared or repaired as above. If the DPC is too low, then it can be pulled followed by firm digital pressure for 40-50mins. Check distal pulse, leg sats.
  - Close incision in multiple layers (0 and 2-0 Vicryl) (the more the better to prevent lymphatic leak), staple skin
  - Recheck DP/PT pulses / Doppler
2. *Decannulation of the drainage cannula*
- Similar to the VV setting
3. *Specifics to the bedside procedure:*
- Lay patient flat, have vent at 100% FiO<sub>2</sub>, and place cautery pad.
  - Ensure anesthesia support is there to monitor patient and adjust sedation as needed. Typically, will also paralyze patient for the procedure.
  - Prep and drape both groins and venous tubing as above
  - Prepare a sterile back-table on which you can set-up the remainder of your supplies
  - Open up the minor vascular tray and put the following on your back table:
    - Metz scissors
    - Multiple small vascular clamps
    - 2 x De Bakeys
    - Castro needle driver
    - Regular needle driver
    - Satinsky clamp, plus additional vascular clamps
  - Open remainder of sterile supplies
  - Set up cautery and sterile suction.

## XI. Evaluation of bridge to transplant patients

- ICU or transplant team will alert you regarding a patient pre-lung transplant that they anticipate may need ECMO. Ideally this is done when the patient is relatively stable and well before they are at the stage of needing ECMO.
- Confirm that the patient is actively listed for transplant. Generally, pre-transplant patients who still have outstanding requirements to be actively listed are not candidates for ECMO, but there are some exceptions (i.e. if the requirement is relatively minor and transplant team can all but guarantee they will be listed shortly).
- Gather the following information about the patient and current admission:
  - Etiology of lung disease and cardiac function over time.
  - Why was the patient admitted and what is causing their decline? Is it something potentially reversible and treatable (infection, PE, volume overload or acute disease flare up) or natural progression of disease?
  - What support are they currently requiring? Are they on max HFNC and NRB at rest and still desaturating, or do they have room for additional support and therapies (e.g. iNO, dobutamine) prior to ECMO? Though these therapies are likely only temporizing, they may buy some time in an acutely decompensating patient.
  - What are they currently able to do with PT? If walk distance is limited (under several hundred feet), how long has it been so poor? Does the patient look frail with little muscle mass or like a robust person who declined quickly and could bounce back quickly after being in bed for a couple of days?
  - Is there concern for active, worsening, or potentially uncontrolled infection? Infections are often the precipitant for a decline, but one of the most common reasons for patients to be placed on hold or de-listed for transplant is uncontrolled infection. Note WBC, fever trend as well as cultures (especially blood).
  - Is there any other end-organ failure (mainly kidneys)?
- Many patients with chronic lung disease have some degree of pulmonary hypertension or RV dysfunction (known, stable or worsening, or new), which should improve with decreased PAPs after transplant and RV remodeling over time, and so is not a barrier to transplant. Significant left heart dysfunction is something that would preclude safe transplant.
  - On cath, the most important things are PAP (ECHOs only give estimate) and PCWP. Record when the cath was done (may sometimes be years ago), and right heart evolution over time on ECHOs. Also want to make note of L heart function including valvular dysfunction (significant aortic insufficiency would worsen with femoral VA support), and other significant comorbidities (CAD, PAD, coagulopathies, etc.).
  - Make sure there is a recent ECHO (ie. one done within the time of their current decline) and BNP. Most frequently, getting a repeat echo when discussing potential BTT patient will be helpful, allowing to compare to prior and to discuss cannulation strategy, but also to get a new baseline to refer to during the bridge
  - These patients can deteriorate very quickly and may need ECMO sooner than later. The signs that these patients are worsening include persistent tachycardia, hypotension, and an increasing creatinine. These clinical changes are signs of worsening pulmonary hypertension and right ventricular dysfunction.
- Discuss the patient with the ECMO attending, ICU team, and transplant team. Alert thoracic surgery attending if he or she is not aware yet.
- If patient is deemed to be an acceptable candidate, start working to have the patient admitted to ICU sooner than later:

- Start working to get the patient lined up as this will be needed for optimal monitoring and for cannulation: central line or PICC line, **right** radial arterial line
- Get a patient ABG
- Discuss support needs (VA vs VV, possible V-AV), timing, crash plan, etc.
  - Historically, most ILD patients even without known PH have worsening PAP and RH function over time and have needed some degree of arterial support. They also appeared to do worse if started on VV and then reconfigured to VA or V-AV. However, with decreased wait-times to transplant and the complications of upper body VA (stroke, bleeding, arm hyperperfusion, etc), there has been more of a shift to start with VV in ILD patients if RV dysfunction is absent and recent PA pressures are normal. If there is evidence of worsening RV dysfunction (hypotension with desaturation, increasing tachycardia, worsening function on ECHO, increasing BNP, inability to work with PT due to above), the patient is usually supported with adjunct measures (inotropy, iNO, diuresis) (or if more emergent, converted to VAV at bedside) until they can be converted to central VA in the OR.  
Conversely, most CF patients, even with RV dysfunction, are bridged just with VV. In these patients, they usually have a larger component of hypercarbic respiratory failure and should be considered for Crescent or Avalon cannula.
  - Measure patient vessels (bilateral femoral veins and common femoral arteries, bilateral jugular veins) diameter on US.
  - Discuss patient with transplant surgeon; discuss feasibility of central vs upper body if needed based on patient anatomy, need to involve CT/Koji/ Yuji etc.
- Discuss ECMO with the patient and family.



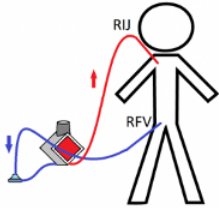
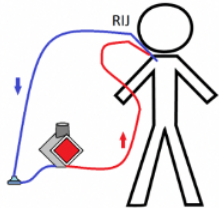
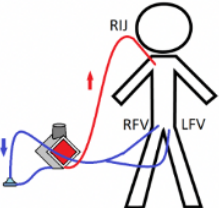
## XII. Tips and tricks

- For transports, discuss cannulation plan with perfusion prior to leaving but bring backup cannulas and backup cannula sizes in case the patient is a different size than anticipated.
- Emphasize the need for bedside US, arterial line, central line, and consenting surrogate with the OSH medical attending. These will all delay cannulation if not anticipated. In the rare case no surrogate exists, cannulation can occur following consent by the CMO / COO (see appropriate section).
- Always bring the back-up ECMO circuit on the transport and into the outside hospital. Its need is usually emergent (for example, if the initial oxygenator clots off soon after going on), and the potential time delay of having someone run back to the ambulance should be avoided.
- Family discussions:
  - Immediately begin talking to the family after your brief initial assessment of the patient. It can take up to a half hour to obtain consent and discuss about ECMO. If consent will be obtained over the phone, consider calling prior to leaving or en route.
  - Briefly review the patient's history. There can be huge gaps in the story that the OSH provides with what the family says, some big enough to impact the patient's candidacy for ECMO (such as cardiac arrest or severe bleed).
  - Have a frank discussion with the patient's family – they should be aware how serious the patient's condition is and that it is a huge decision to commit to ECMO. Make sure that they understand that ECMO is not a survival guarantee and that the risk of death even with ECMO is significant. Discuss general ECMO complications (in particular, bleeding, blood clots, stroke) and cannulation complications (at a minimum: bleeding, injury to structures nearby the cannulation vessels, and hemodynamic instability peri-cannulation). They will almost always appreciate an honest discussion about their family member's condition, what ECMO can reasonably achieve, and potential complications.
- Cannulation
  - If you anticipate having a hard time accessing or visualizing the femoral vein (large habitus, extensive SQ emphysema obscuring US) and may not be confident in your access, have X-ray come STAT and place a flat plate under the patient's abdomen to check wire position. If venous pressure is high and you are concerned about an arterial stick you can also place a small (4-5Fr) sheath over the wire and transduce using a central line kit to ensure venous placement.
  - The 25Fr Multiport cannula can easily be inserted if the vessel has been dilated to 24Fr (the largest dilator in the Estech kit). The Biomedicus end-hole and EOPA cannulas aren't as easily inserted (they have less tapered obturators and are slightly floppier), and you sometimes need to use just the tip of a larger French dilator to dilate the skin to facilitate insertion (i.e. dilate with the tip of the 24Fr dilator before inserting the 23Fr Biomedicus, or with the tip of the 20Fr dilator before inserting the 18Fr EOPA). For the larger 27-29Fr Biomedicus or Maquet cannulas, you can use the internal obturator to further dilate the vessel past 24Fr or you can use the MC3 or Avalon dilator kits that provide up to 28 or 30Fr dilators, respectively, in order to achieve sufficient dilation.

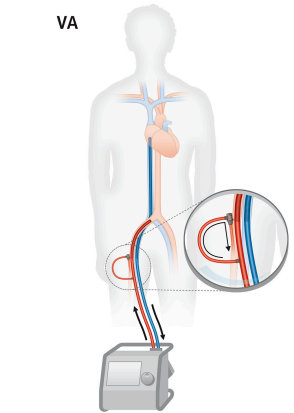
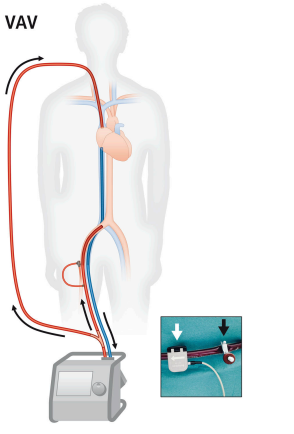
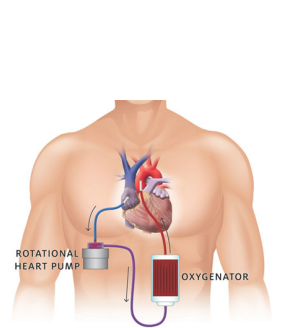
**XIII. Tips and tricks**

	<b><u>VV ECMO</u></b>	<b><u>VA ECMO</u></b>
<b><u>Purpose</u></b>	Respiratory support	Hemodynamic support
<b><u>Cannulation sites</u></b>	<p><b>Dual cannulation sites:</b></p> <ul style="list-style-type: none"> <li>- <u>Drainage:</u> femoral vein (one or both*)</li> <li>- <u>Reinfusion:</u> femoral vein or internal jugular vein</li> </ul> <p><b>Single cannulation site:</b></p> <ul style="list-style-type: none"> <li>- Dual lumen in R internal jugular</li> </ul>	<p><b>Peripheral:</b></p> <ul style="list-style-type: none"> <li>- <u>Drainage:</u> femoral vein, possible internal jugular</li> <li>- <u>Reinfusion:</u> femoral artery, possible subclavian artery, carotid artery in pediatric cases</li> </ul> <p><b>Central:</b></p> <ul style="list-style-type: none"> <li>- <u>Drainage:</u> right atrium</li> <li>- <u>Reinfusion:</u> aorta</li> </ul>
<b><u>Indications</u></b>	<ul style="list-style-type: none"> <li>- Acute respiratory failure (ARDS)</li> <li>- Acute-on-chronic respiratory failure (bridge to lung transplantation, primary graft dysfunction post lung transplant)</li> </ul>	<ul style="list-style-type: none"> <li>- ECPR in cardiac arrest</li> <li>- Cardiogenic shock               <ul style="list-style-type: none"> <li>- Acute MI</li> <li>- Failure to wean CPB</li> <li>- Primary graft dysfunction post heart transplant</li> </ul> </li> <li>- RV failure               <ul style="list-style-type: none"> <li>- RV decompensation in pulmonary hypertension</li> <li>- Acute PE</li> </ul> </li> </ul>
<b><u>Weaning</u></b>	<p>Wean sweep</p> <p>Monitor saturation and ABG</p>	<p>Wean flow</p> <p>Monitor hemodynamics and echo</p>
<b><u>Problems</u></b>	<p>VV ECMO flow must be above 60% of CO to achieve good oxygenation. Limiting factor is most frequently drainage cannula size: some patients needing very high flows will need extra drainage cannula</p> <p>*<u>Solution:</u> addition of a drainage cannula and conversion to VV-V will allow more drainage</p>	<p>Patients cannulated onto fem-fem VA who present poor lung function may experience dual circulation in which coronaries and upper body are perfused with poorly oxygenated blood from the residual or recovering LV ejection.</p> <p><u>Solution:</u> addition of a venous reinfusion cannula in an internal jugular vein and conversion to V-AV will shunt oxygenated blood through the lungs</p>

**SPECIFICS OF VENO-VENOUS ECMO**

<p><b><u>Dual site VV</u></b></p>		<p><b>Indications:</b></p> <ul style="list-style-type: none"> <li>- ARDS / bridge to recovery</li> <li>- ECMO Transports</li> </ul> <p><b>Cannulas:</b></p> <ul style="list-style-type: none"> <li>- Drainage: multiport 23, 25 or 29Fr (the largest possible)</li> <li>- Reinfusion: EOPA 18, 20 or 22Fr</li> </ul> <p><b>Low PaO<sub>2</sub>:</b> Increase flows, potentially convert to VV-V</p>
<p><b><u>Single site, dual lumen VV</u></b></p>		<p><b>Indications:</b></p> <ul style="list-style-type: none"> <li>- ARDS / bridge to recovery</li> <li>- Bridge to transplant</li> </ul> <p>*** need to be placed under fluoro ***</p> <p><b>Cannulas:</b></p> <ul style="list-style-type: none"> <li>- Avalon</li> <li>- Crescent (the largest possible)</li> </ul> <p><b>Low PaO<sub>2</sub>:</b> Increase flows, potentially convert to dual site VV</p>
<p><b><u>VV-V</u></b></p>		<p><b>Indications:</b></p> <ul style="list-style-type: none"> <li>- ARDS / bridge to recovery requiring very high flows</li> </ul> <p><b>Cannulas:</b></p> <ul style="list-style-type: none"> <li>- Drainage: baseline MP + second 19, 21 or 23Fr MP or endhole</li> <li>- Reinfusion: EOPA 18, 20 or 22Fr</li> </ul> <p><b>Low PaO<sub>2</sub>:</b> Convert to central</p>

**SPECIFICS OF VENO-ARTERIAL ECMO**

<p><b>Peripheral VA</b></p>	<p align="center">VA</p> 	<p><b>Indications:</b></p> <ul style="list-style-type: none"> <li>- Cardiogenic shock (acute LV failure from MI)</li> <li>- RV failure from decompensated pulmonary hypertension, acute PE</li> </ul> <p><b>Cannulas:</b></p> <ul style="list-style-type: none"> <li>- Drainage: multiport 23, 25 or 29Fr (the largest possible)</li> <li>- Reinfusion: arterial 14, 15Fr (17 or 19Fr possible, but in very large arteries only)</li> <li>- May need distal perfusion cannula in SFA: 6 or 7Fr</li> </ul> <p><b>Low PaO<sub>2</sub>:</b> HFNC, add iNO, potentially convert to V-AV</p>
<p><b>Peripheral V-AV</b></p>	<p align="center">VAV</p> 	<p><b>Indications:</b></p> <ul style="list-style-type: none"> <li>- pVA patients with dual circulation</li> </ul> <p><b>Cannulas:</b></p> <ul style="list-style-type: none"> <li>- Add an 18 or 20Fr EOPA in internal jugular</li> <li>- Split the reinfusion lines</li> </ul> <p>*** need a Hoffman clamp on the IJ reinfusion line to tailor split flows as the downstream vascular bed in the IJ has a lower pressure than the arterial bed ***</p> <p><b>Low PaO<sub>2</sub>:</b></p> <ul style="list-style-type: none"> <li>- Increase and tailor the split reinfused flows, add HFNC, add iNO</li> <li>- Convert to central VA</li> </ul>
<p><b>Central VA</b></p>	 <p align="center">ROTATIONAL HEART PUMP      OXYGENATOR</p>	<p><b>Indications:</b></p> <ul style="list-style-type: none"> <li>- Bridge to transplant patients presenting issues with peripheral cannulas or anticipated long-term support need</li> </ul> <p><b>Cannulas:</b></p> <ul style="list-style-type: none"> <li>- Drainage: 28, 30 or 32Fr single stage RA drainage cannula</li> <li>- Reinfusion: EOPA 18, 19 or 20Fr</li> </ul> <p>*** 2<sup>nd</sup> or 3<sup>rd</sup> R anterior ICS minithoracotomy ***          *** All purse-strings need to be pledgeted with bovine pericardium ***          *** tunnel the cannulas towards the axilla ***</p> <p><b>Low PaO<sub>2</sub>:</b> Increase flows, HFNC</p>